Current Science International Volume : 06 | Issue : 02| April-June|2017
ISSN 2077-4435 Pages: 292-302

Macroscopical and Scanning Electrone Microscopical Studies on the Rectal Caeca of Three Different Habitually Feeding Birds

[1]Ragaa M. El Deeb, [2]Abdel Razik H. Farrag, [3]Samia M. Abd El Wahab and [3]Shimaa A. Eltatawy

[1]Department of Zoology, Faculty of Science, Ain Shams University, Cairo, Egypt.
[2]Pathology Department, Medical Research Division, National Research Centre, Cairo, Egypt.
[3]Department of Zoology, Faculty of Science, Al AZhar University, Cairo, Egypt.

Received: 20 February 2017 / Accepted: 10 April / Publication Date: 15 April 2017

ABSTRACT

The present investigation was carried out to study the variations of the morphology and scanning electron microscopy of rectal caeca in three birds, *Coturnix coturnix*, *Cairina moschata* and *Athene noctua* to understand the role of caeca in digestion. This study shows that, there is a great difference in the caecal morphology and structures between the three selected birds. The present findings revealed that the rectal caeca are composed of three regions, proximal, middle and distal. Also the caeca show different colours as well as asymmetrical lengths. At the level of the scanning electron microscope study there is a great difference in the mucosal sculpturing (micro-ornamentation) between the three selected birds. These differences can be related to the environmental habits preferences of the birds and support those of other studies that the caecal development is related to diet.

Key words: Rectal caeca - Morphology – Scanning - Mucosal micoornamentation.

Introduction

Avian caeca are blind-ending sacs that extend from the proximal end of the colon. They range in size from large and paired to small and single or may be completely absent. Each caecal sac consists of 3 parts: proximal part or base, middle and distal part or apex. In most birds, right and left caeca arise laterally at the junction of the small and large intestines; in a few species, the caeca open into the rectum ventrally or dorsally. In some species (e.g., herons, bitterns), only one caecum is present and in the secretary bird, there are two pairs of caeca (McLelland 1989). A relationship between the size of the caeca and diet has been proposed (Meyer 2009). In this connection, it is of interest that some carnivores have caeca that are poorly developed and often vestigial (hawks); in others, they are very long and expanded like in owls (Hellmann, 2007). The examined birds in this study; quails, ducks and owls have the best developed caeca (Clench & Mathias, 1995). In this study, the caeca of the three habitually different birds were examined to reveal the different patterns as well as establishing of basal data on the different sculpturing of the mucosal surface of the caeca of the three birds.

Material and Methods

Animals:

In the present work, birds from three different feeding habits were selected. Five adult healthy birds of each sex were obtained from 1- a quail farm in Kaffr Elshikh, *Coturnix coturnix* (common quail), 2- a duck farm in Cairo, *Cairina moschata* (Muscovy duck) and 3- trapped alive from caves in Abo-Rwash area of Giza pyramids, *Athene noctua* (little owl). The specimens were sacrificed and rapidly dissected (Fig.1 A, B and C).

The macroscopic observations:

The orifice, position, shape and the color of right and left caeca were recorded and the caeca of each bird were isolated at the iliocaecal junction and separated from mesenteries and iliocaecal

Corresponding Author: Shimaa A. Eltatawy, Department of Zoology, Faculty of Science, Al AZhar University, Cairo, Egypt. E-mail: gomana700@gmail.com

ligaments. The digestive tracts as well as caeca were gently straightened on a flat plane and the full length of digestive tract and each caecum measured using slide calipers. The percentages of mean length of caeca related to the length of the digestive tract were reported. The differences between the length of right and left caeca also analyzed.



Fig. 1: Photographs of the (A) common quail, (B) Muscovy duck and (C) little owl.

The Preparation of samples for Scanning Electron Microscope (SEM):

For scanning electron microscope the caecal tissues divided into 3 equal segments: proximal (closest to ileocaecal junction), middle, and distal (blind end). All caecal regions samples: proximal, middle, and distal were:

1- fixed in 4% glutaradehyde in 0.2 M sodium cacodylate buffer (pH7.3) for 4 hrs., then post fixed in 1% aqueous OsO_4 for 2 hrs.
2- rinsed three times in the same buffer (sodium cacodylate buffer).
3- dehydrated through a graded ethanol series from 10 -100%, 10 min. in each one except the last one 100% for 30 min. for three changes.
4- dehydrated using Critical Point Dried instrument with liquid CO_2 and mounted on cupper stubs with double- sided adhesive tape, coated with gold using S150A Sputter Coater (Edwards-England).
5- The specimens were examined and photographed by using of scanning electron microscope (Quanta FEG 250) in National Research Centre, Dokki, Cairo.

Results

I - The macroscopic observations:

a-The orifice and position:

The caeca of all three birds are paired. The paired caeca of duck and owl arise from the lateral walls of the rectum opposite one another, close to the junction with the ileum. While in quail, it arises ventrolaterally. Both the caeca are located in the intestinal peritoneal cavity and attached to the ileum by the peritoneal folds called ileo-caecal ligaments (Fig. 2 A, B and C).

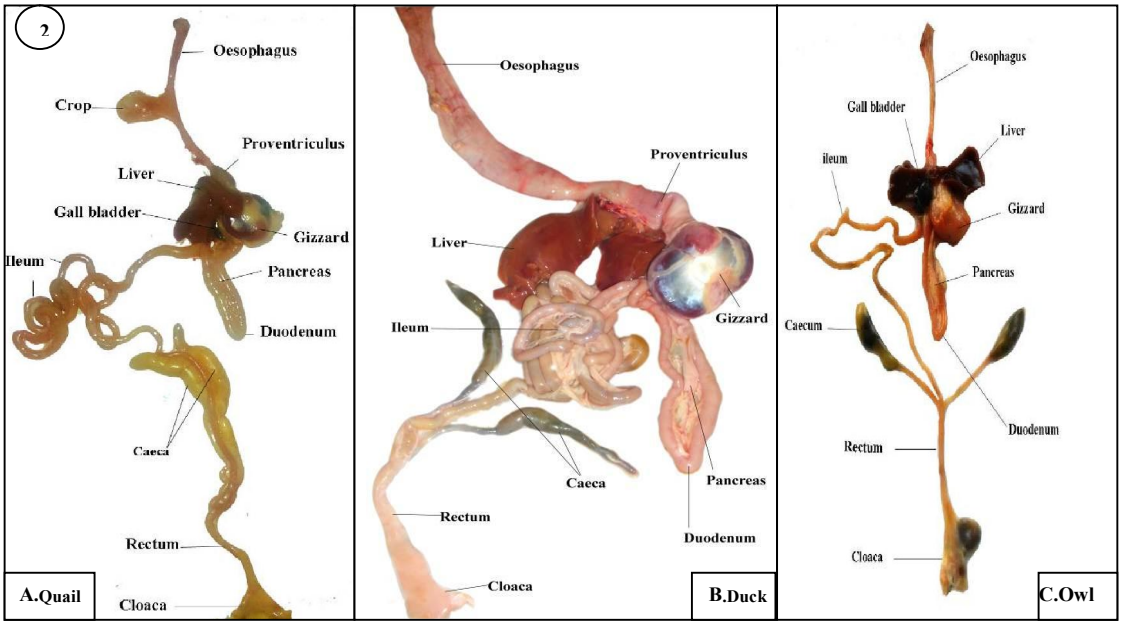

Fig. 2: Photograph show the alimentary canal and orifices of caeca of the (A) common quail, (B) Muscovy duck and (C) little owl.

b-The shape and colour:

The shape of the proximal region in the three birds is long narrow cylindrical neck. In quail caeca it began with dome-like protrusions which hemispheric or spherical in shape and represented caecal tonsil. The middle part of quails is long and narrow. In owls it is long and narrow and becomes ampullated at the end of this zone. While in ducks caeca the middle zone has expanded leaf like shape. The distal zone of each caeca has a different shape; it has a falciform sac with rounded tip in quail caeca but in ducks it has a pointed end. However in owls the distal zone appears as a sac with rounded end (Fig. 3). The colour of caeca differs in each bird depending, on if the caeca full or empty. When they are empty they appear in quails, ducks and owls as dark salmon, grayish pale yellow and umber brown respectively. When they are full the colour appears in quails, ducks and owls as maize, dark green and dark olive green respectively (Fig. 3).



Fig. 3: A photograph explains the shape and colour of caeca of common quail, Muscovy duck and little owl. (R. C. is Right caecum and L. C. is Left caecum).

c- Mean length of the caeca and its percentages related to the length of the digestive tract:

In quail, the results of the mean values of length of right and left caecum are 6.89 ± 0.22 and 7.5 ± 0.27 cm respectively. No significant difference is found between the length of the left and right caecum at $P < 0.05$. The percentage of these means gives values nearly equal 7.9% and 8.5% of the total length of the alimentary canal (Table 1).

The mean values of right and left caeca of ducks are 12.2 ± 0.62 cm and 13.67 ± 0.75 cm respectively, and the percentages exhibit about 5.2% and 5.9 % of the total length of the alimentary canal. No significant difference is found between the length of the left and right caecum at $P < 0.05$ (Table 1).

In case of owl, the findings shows that the mean values of length of right and left caeca are 4.51 ± 0.06 and cm 4.76* ± 0.09 cm respectively and its percentages nearly equal 9.1% and 9.8%. There is a significant increase found in the length of the left caecum at $P < 0.05$ as compared with right one (Table 1).

Table 1: The difference of mean length between right and left caeca of the three birds.

	Value of mean length		
	Quail caeca	Duck caeca	Owl caeca
Right caeca	6.89 ± 0.22	12.2 ± 0.62	4.51 ± 0.06
Left caeca	7.5 ± 0.27	13.67 ± 0.75	4.76* ± 0.09
T-test (p< .05)	0.10	0.15	0.04

II – Scanning electron microscopy:

a- The proximal zone:

In quail, scanning electron microscope examination of ceacal tonsil shows the aggregated masses of the lymphoid tissues in addition to few numbers of villi. The remaining part of the proximal zone shows the presence of numerous villi (Figs. 4 & 5). These villi exhibited different shapes like, leaf, tongue and finger or branched finger shapes (Fig. 6).

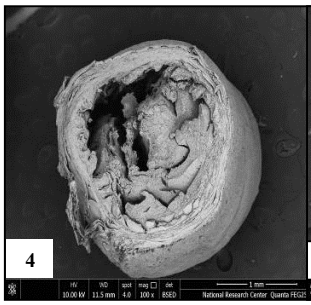

Fig. 4: SEM micrograph of the cross section of the caecal tonsil of proximal zone of the quail caeca shows aggregation of lymphoid tissues (Scale bar: 1 mm).

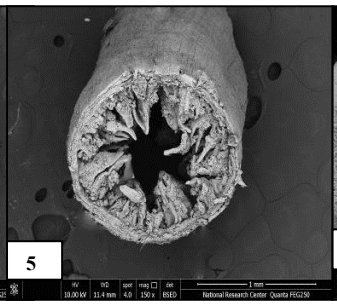

Fig. 5: SEM micrograph of the cross section of the proximal zone of the quail caeca (Scale bar: 1 mm).

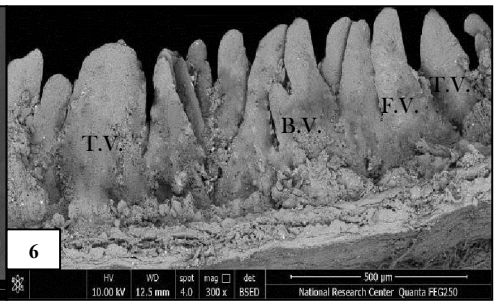

Fig. 6: SEM micrograph of the proximal zone of the quail caeca, leaf-like villi (L-V), tongue-like villi (T-V), finger-like villi (F-V) and branched finer like (B-V) (Scale bar: 500 µm).

The proximal zone of duck caeca shows the presence of number of villi with leaf shape mainly in addition to tongue like shape (Figs. 7&8).

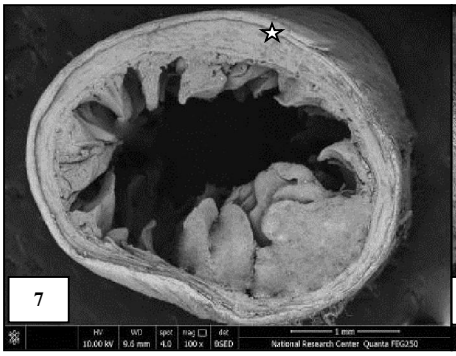

Fig. 7: SEM micrograph of the cross section of the proximal zone of the duck caeca shows muscularis thickness (star) (Scale bar: 1 mm).



Fig. 8: SEM micrograph of the proximal zone of the duck caeca shows tongue like villi (T-V) and leaf like villi (L-V) (Scale bar: 500 µm).

In owl caeca, the proximal zone shows the presence of great number of villi (Fig. 9). These villi exhibited a tongue-like shape, leaf-like shape or foot-like shape. Occasionally, the villous surface is pitted by circular or oval holes of the goblet cells. The outlines of individual epithelial cells are flat-topped or gently convex outwards and take a honeycomb- like appearance on the villous surface (Figs. 10 and 11).

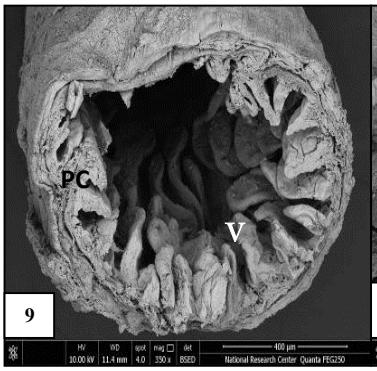

Fig. 9: SEM micrograph of a cross section of the proximal zone of the little owl caeca shows villi (V) and plicae circulares (PC) (Scale bar: 400 µm).



Fig. 10: SEM micrograph of the proximal zone of the little owl caeca shows tongue-like shape villi (T-V), leaf-like shape villi (L-V), foot-like shape villi (F-V) and opening of goblet cells (arrows) (Scale bar: 200 µm).



Fig. 11: SEM micrograph of a magnified part of the proximal zone of the little owl caeca shows a honeycomb appearance of epithelial cells on the villous surface (arrow) (Scale bar: 20 µm).

b- The middle zone:

The middle zone of the quail and duck caeca shows the presence of numbers of high plicae circulares (Fig. 12). The surfaces of the middle zone of the quail caeca shows the presence of great numbers of volcano like shape of crypts opening and absence of villi (Fig. 13).

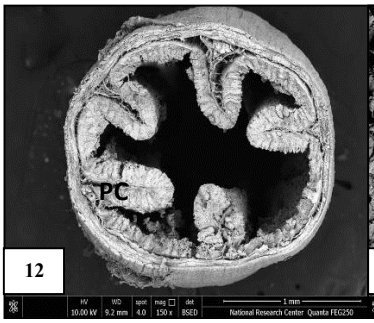

Fig. 12: SEM micrograph of the cross section of the middle zone of the quail caeca shows plicae circulares (PC) (Scale bar: 1 mm).

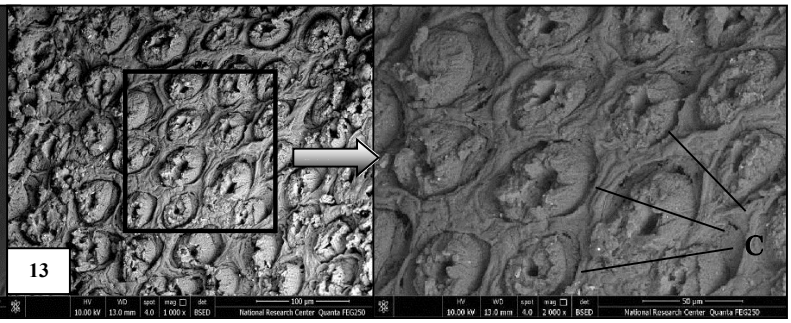

Fig. 13: SEM micrograph of the middle zone of the quail caeca (scale bar: 100 µm) shows crypts opening (C) in the enlarged part (Scale bar: 50 µm).

Fig. 14: SEM micrograph of a cross section of the middle zone of the duck caeca, plicae circulares (PC) (Scale bar: 1mm).



Fig. 15: SEM micrograph of the middle zone of the duck caeca (Scale bar: 500 µm) and magnified part shows interfering nets appearance of mucosa (Scale bar: 400 µm).

The middle zone of the owl caeca shows presence of tongue-like villi (Fig. 16).



Fig. 16: SEM micrograph of a cross section of the middle zone of the little owl caeca (Scale bar: 500 µm).

The sunflower- shape of the opening of crypts at the base of the villi appeared clearly. On the villous surface a honeycomb appearance of the epithelial cells as well as the pits of the goblet are observed (Figs. 17a, b and c).

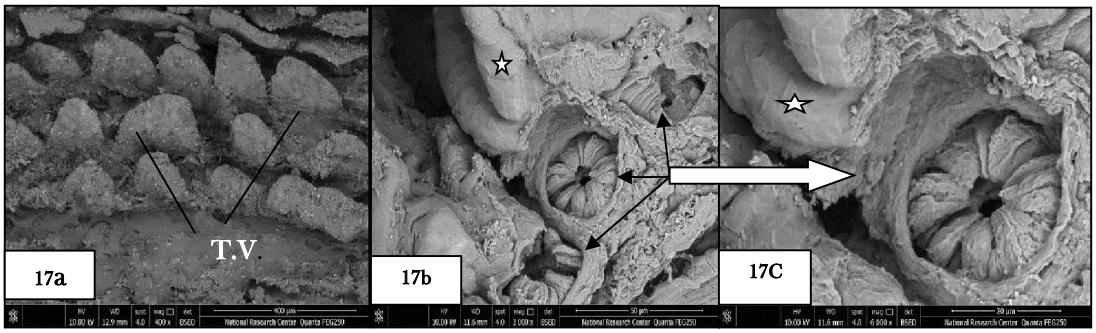

Fig. 17a: SEM micrograph of the middle zone of the little owl caeca shows tongue-like shape villi (T-V) (Scale bar: 400 µm).

Fig. 17b: SEM micrograph of a longitudinal section of middle zone of the little owl caeca shows opening of crypts (arrows) and honeycomb appearance (stars) (Scale bar: 50 µm).

Fig. 17c: Magnification of a part of figure (17b) shows the honeycomb appearance (stars) and sunflower appearance of crypt (Scale bar: 20 µm).

c- The distal zone:

The distal zone of the quail and duck caeca shows a reduction in the height of plicae circulars (Figs. 18, 21 and 22).

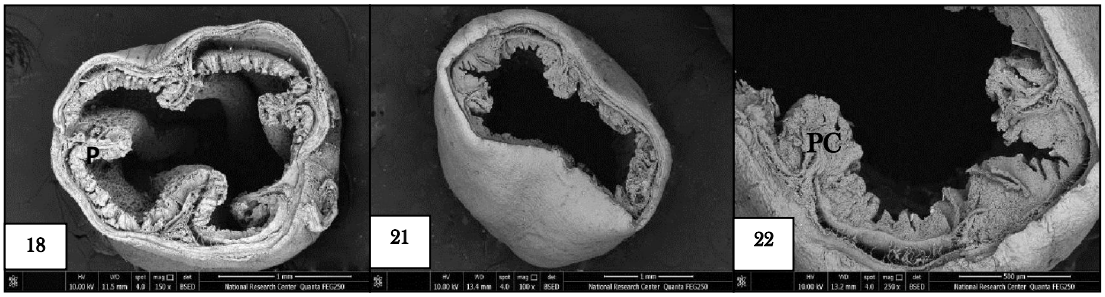

Fig. 18: SEM micrograph of the cross section of the distal zone of the quail caeca, plicae circulars (PC) (Scale bar: 1mm).

Fig. 21: SEM micrograph of the cross section of the distal zone of the duck caeca (Scale bar: 1mm).

Fig. 22: SEM micrograph of a magnified part of the cross section of the distal zone of the duck caeca showing height of plicae circulares (PC) (Scale bar: 500 µm).

The surface of plicae circulares appears in quail caeca like a net and the openings of crypts in-between it. The crypts openings differ from volcano to sea anemone shape due to presence of microvilli on its surface (Figs. 19 and 20). The distal part of duck caeca shows wrinkle surface of plicae circulares and the mucosal surface with many cavities in-between (Fig. 23).

The distal part of owl caeca shows a saw-shape of the mucosa and absence of villi (Fig. 24). This zone also showed the presence of great number of parallel-ridged tract of small mucosal folds (Fig. 25).



Fig. 19: SEM micrograph of the distal zone of the quail caeca shows crypts opening (C) and plicae circulares (PC) (Scale bar: 200 µm).



Fig. 20: SEM micrograph of the distal zone of the quail caeca, the microvilli on opening of crypts giving it sea anemone shape (arrow) (Scale bar: 20 µm).



Fig. 23: SEM micrograph of the longitudinal section of the distal zone of the duck caeca shows wrinkle surface of the mucosal surface (Scale bar: 500 µm).

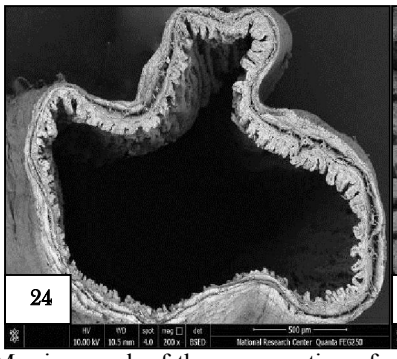

Fig. 24: SEM micrograph of the cross section of the distal zone of the little owl caeca (Scale bar: 500 µm).



Fig. 25: SEM micrograph of the distal zone of the owl caeca shows parallel mucosal folds (Scale bar: 400 µm).

Discussion

The present investigation is proposed to study, in a comparative manner, the morphological and ultra structures of the caeca in a granivorous bird, common quail (*Coturnix coturnix*); omnivorous bird, Muscovy duck (*Cairina moschata*) and carnivorous bird, little owl (*Athene noctua*). The correlation between the structure of the caeca of birds and their feeding habits demonstrates a close relationship between the caecal structure and the type of food eaten by the birds. These results consistent with previous studies which reported that the caeca of quail, duck and owl are long well developed caeca (strong *et al*., 1990; Clench and Mathias, 1995; DeGolier *et al*. 1999; Działa-Szczepańczyk 2006; Działa-Szczepańczyk and Charuta 2009; Svihus *et al*., 2013).

The caeca attached to the ileum by the peritoneal folds called ileo-caecal ligaments and located in the intestinal peritoneal cavity, with the caecal bodies on the right side of the body and arose laterally into the walls of the rectum opposite one another, close to the junction with the ileum and this result is very similar to those observed in other birds by (Bailey *et al*. 1997; DeGolier *et al.* 1999; Działa-Szczepańczyk 2006; Meyer *et al.* 2009 and Firdous and Lucy 2012).

On the other hand, the caeca in common quail arose ventrolaterally into the walls of the rectum opposite one another and this is coincides with that found in Japanese quail (Usha Kumary *et al*., 2009) and common quail (Zaher *et al*., 2012).

The caeca in the three birds divided into three zones, proximal and middle zones followed by a distal zone.

The proximal zone in all birds appears as long narrow cylindrical neck. A dome-like protrusions represented caecal tonsils are observed in the common quail caeca and this is similar to the results

observed by Kitagawa *et al.* (1998); Akter *et al*. (2006); Rezaian and Hamedi (2007) and Usha Kumary *et al.* (2009).

The middle zone is long, narrow and cylindrical in quail followed by ampullated part in the owl but in duck appears as expanded leaf like body. The distal zone is falciform sac with rounded end in quail, rounded end apex in owl and pointed end apex in duck.Such description is in accordance with that found in Japanese quail (Usha Kumary *et al*., 2009), common quail (Zaher *et al*., 2012), duck in general (Kitamura *et al*., 1976; Bailey *et al*., 1997 and Firdous and Lucy, 2012) and in some owls and carnivorous birds (Clench and Mathias, 1995; Hassouna, 2001; Meyer *et al*., 2009; Mot, 2010 and Hussein and Rezk, 2016).

The colour of caeca of the three birds is in consistent with that described by Bailey *et al*. (1997) and Alaeinovin *et al*. (2013) who stated that, the colour appears variable depending on if the caeca full or empty and on the kind of the diet.

Działa-Szczepańczyk (2006) stated that the asymmetry of even internal organs of animals is a commonly observed phenomenon in nature and is called the bilateral asymmetry

The mean values of length of right and left caeca of quail were 6.9 cm and 7.5 cm respectively and these results agree with that recorded by Clench and Mathias, (1995).

However, DeGolier *et al*. (1999) study seven species of Anatidae including the eight omnivorous muscovy ducks (*Cairina moschata*) and reported that the mean value of length of caeca is 12.8 ± 1.2 cm and this result is in conformity with our result.

On the other hand, Clench and Mathias, (1995) and Meyer *et al*. (2009) stated that the length of owl caeca is vary and range from 4 to 11cm while DeGolier *et al.* (1999) studied five species of Strigidae including seven individual of Athene genus and reported that the mean value of length of caeca is 4.6± 0.3 cm and these results are homologous to the present work.

The recent study indicated that, there is no significant increase in mean length of left caeca when compared with the right caeca or between males and females of quail (Kitagawa *et al*., 1998; Majeed *et al*., 2009 and Usha Kumary *et al*., 2009) and in duck as in Działa-Szczepańczyk and Betlejewska (2003) and Działa-Szczepańczyk and Charuta (2009).

On the other hand, the mean value of length in owl in this study indicated that the left caecum was longer than the right one but there is a significant increase when compared with the right caecum as in long-tailed carnivorous duck *Clangula hyemalis* (Działa-Szczepańczyk, 2006).

The recent study recorded that, the scanning electron observations of the three birds showed the presence of great number of villi with different shapes in the proximal zone and explain the honeycomb appearance of the individual epithelial cells on the villous surface in the owl caeca. Such results are found in the different parts of the small intestine and caeca of many animals (Dahm *et al*., 1980; Kadhim *et al*., 2010 and Abo-Eleneen *et al*., 2014).

The middle zone of the quail and duck showed presence of number of high plicae circulars, crypts opening and absence of villi these results are in agreement with that found in (Dantzer *et al*., 1989; strong *et al*., 1990; Ferrer *et al*., 1991and Chen *et al*., 2002).

On the other hand, the middle zone of the owl shows presence of some villi and absence of plicae circulars and these findings are similar to that found in Kiwi (Potter *et al*., 2006).

The distal zone of the three birds showed that, absence of villi and presence of many parallel ridges. Such finding are reported in all researches about caeca (Fenna and Boag, 1974; Dantzer *et al*., 1989; strong *et al*., 1990; Ferrer *et al*., 1991; Chen *et al*., 2002 and Potter *et al*., 2006).

We can conclude from the present study that the morphological and ultrastructural differences in the caeca among the three examined birds exhibited important specific features reflecting the mode of life and feeding habits of these birds. We indicated that, the well developed caeca occur in omnivorous, some granivorous in addition to some carnivorous species. However this development is due to that, species those consuming the cell walls of plant seeds (granivorous) and those consuming the greens, fruits and insects (omnivorous) would be expected to have a well developed caeca. The relatively well developed caeca in non herbivorous species (little owl) are may be associated with the conservation of critical resources such as water and nitrogen.

References

Abo-Eleneen, R., A. El-Bakry and A. Abdeen, 2014. Ultrastructural study of the alimentary tract of two reptilian species the lizard *Scincus scincus* and the snake *Natrix tessellate*. J. Cytology and Histology, 4 (010): 1-7.

Akter, S., M. Khan, M. Jahan, M. Karim and M. Islam, 2006. Histomorphological study of the lymphoid tissues of broiler chickens. Bangladesh Journal of Vet. Med., 4(2): 87-92.

Alaeinovin, A., I. Pousty, H. Ghilanpour and I. Sohrabihaghdoust, 2013. Morphology of large intestine in ostrich chickens. Annals of Biological Research, 4(2): 297-301.

Bailey, T., E. Mensah-brown, J. Samour, J. Naldo, P. Lawrence and A. Garner, 1997. Comparative morphology of the alimentary tract and its glandular derivatives of captive bustards. J. anat., 191: 387-398.

Chen, Y., H. Hsu and J. Hsu, 2002. Studies on the Fine Structure of Caeca in Domestic Geese. Asian-Aust. J. Anim. Sci., 15(7): 1018-1021.

Clench, M. and J. Mathias, 1995. The avian caecum: review. Wilson Bull., 107(1): 93-121.

Dahm, H., U. Schramm and W. Lange, 1980. Scanning and transmission electron microscopic observations of the cloacal epithelia of the domestic fowl. Cell tissue res., 211: 83-93.

Dantzer, V., 1989. Ultrastructural components of differences between the two major chicken ceca. J. of experimental supplement, 3: 321-31.

De Golier, T., S. Mahoney and G. Duke, 1999. Relationships of avian caecal lengths to food habits, taxonomic position and intestinal lengths. The condor, 101(3): 622-634.

Działa-Szczepańczyk, E. and K. Betlejewska, 2003. Morphology and morphometry of caeca in the black scoter *Melanitta nigra*. Electronic Journal of Polish Agricultural Universities, 6(2): -07.

Działa-Szczepańczyk, E., 2006. Morphometric characteristic of the caecum in long-tailed ducks *clangula hyemalis* wintering on the polish Baltic coast. Electronic Journal of Polish Agricultural Universities, 9: 40.

Działa-Szczepańczyk, E. and A. Charuta, 2009. Morphology and morphometry of caeca in the tufted duck *Aythya Fuligula*. Zoologica Poloniae, 54(1): 21-31.

Fenna, L. and D. Boag, 1974. Adaptive significance of the caeca in Japanese quail and spruce grouse. Can. J. Zool., 52: 1577-1584.

Ferrer, R., J. Planas, M. Durfort and M. Moreto, 1991. Morphological study of the caecal epithelium of the chicken（Gallus Gallus Domesticus L.）Br. Poult. Sci., 32: 679-691.

Firdous, A. and K. Lucy, 2012. Caecal Development in Kuttanad Duck (*Anas Platyrhynchos Domesticus*). IOSR Journal of Agriculture and Veterinary Science, 1(2): 13-16.

Hassouna, A., 2001. Some anatomical and morphometric studies on the intestinal tract of chicken, duck, turkey, pigeon, dove, quail, sparrow, heron, jackdaw, hoopoe, kestrel and owl. Assiut Veterinary Medical Journal, 44(88): 47-78.

Hellmann, A., 2007. Untersuchungen zu Aufbau und Funktion der Caeca bei Eulen (Strigiformes). Diss. Vet. Med., Univ. Vet. Med. Hannover.

Hussein, S. and H. Rezk, 2016. Macro and microscopic characteristics of the gastrointestinal tract of the cattle egret (*Bublcus ibis*). International Journal of Anatomy and Research, 4(2): 2162-2174.

Kadhim, K., A. Zuki, M. Noordin, S. Babjee and W. Khamas, 2010. Light and scanning electron microscopy of the intestine of the young red jungle fowl (*Gallus gallus*). Journal of Animal and Veterinary Advances, 9(21): 2729-2737.

Kitagawa, H., Y. Hiratsuka, T. Imagwa and M. Uehara, 1998. Distribution of lymphoid tissue in the caecal mucosa of chickens. J. Anat., 192: 293-298.

Kitamura, H., M. Sugimura, Y. Hashimoto, S. Yamano and N. Kudo, 1976. Distribution of lymphatic tissues in duck caeca. Jap. J. vet Res., 24: 37-42.

Majeed, F., F. Al- Asadi, A. Al. Nassir and E. Rahi, 2009. The morphological and histological study of the caecum in broiler chicken. Bas.J.Vet.Res., 8(1): 19-25.

McLelland, J., 1989. Anatomy of the avian caecum. Journal of Experimental Zoology, 252(s3): 2-9.

Meyer, W., A. Hellmann and N. Kummerfeld, 2009. Demonstration of calcium transport markers in the ceca of owls (Aves:Strigiformes), with remarks on basic ceca structure. Eur. J. Wildl. Res., 55: 91-96.

Mot, M., 2010. Morphological aspects of digestive apparatus in owl (*Asio flammeus*) and dove (*Columba livia*). Lucrari stiintifice medicna veterinara, 43(2): 364-367.

Potter, M., R. Lentle, C. Minson, M. Birtles, D. Thomas and W. Hendriks, 2006. Gastrointestinal tract of the brown kiwi (*Apteryx mantelli*). J. of zoology, 270: 429-436.

Rezaian, M. and s. Hamedi, 2007. Histological study of the caecal tonsil in the cecum of 4- 6 months of age white leghorn chicks. American Journal of Animal and Veterinary Sciences, 2(2): 50-54.

Strong, T., P. Reimer and E. Braun, 1990. Morphometry of the galliform cecum: a comparison between Gambel's quail and the domestic fowl. Cell Tissue Res., 259(3): 511-8.

Svihus, B., M. Choct and H. Classen, 2013. Function and nutritional roles of the avian caeca: a review. World's Poultry Science Journal, 69: 249-263.

Usha Kumary, S., S. Venkatesan and R. Geetha, 2009. Microanatomical studies on the caecum of Japanese quail. Indian Journal of Animal Sciences, 79(10): 1011-1014.

Zaher, M., A. El-Ghareeb, H. Hamdi and F. AbuAmod, 2012. Anatomical, histological and histochemical adaptations of the avian alimentary canal to their food habits: I-Coturnix coturnix. Life Science Journal, 9(3): 254-275.