Middle East Journal of Applied Sciences, 3(4): 259-264, 2013
ISSN: 2077-4613

# Partial Parotidectomy Versus Superficial or Total Parotidectomy

**[1]Ibrahim Abde-Albare and [2]Mohamed A. Foda**

*[1]Health Director of Tanta Cancer Center and Head of Surgical Oncology, Egypt*
*[2]Faculty of Dentistry, Al-Azhar University, Assiut Branch,Egypt*

## ABSTRACT

***Background:*** The treatment of benign parotid tumours has shifted from superficial or total parotidectomy to partial parotidectomy in the recent two decade. This study examined whether current surgical techniques improved functional outcomes after surgery for benign parotid tumours. ***Methods:*** twenty six patients were assigned randomly to superficial or total parotidectomy (13 patients) and partial parotidectomy (13) surgery. The latter consisted of modified facelift incision, greater auricular nerve preservation and coverage with parotid fascia. Surgical complications and parotid gland function were monitored during the hospital stay, and 1, 3, 6 ,12 and 24 months after surgery. The assessment was performed through: fin needle function, visual analogue scal and loss of function**.** ***Results****:* The overall complication rate significantly lower in the functional surgery group. In this group, more patients were satisfied with their scars and facial contours, the auricular nerve sensory recovery rate was high, and transient facial paralysis and Frey's syndrome were infrequent (4 and 2% respectively). Stimulated salivary flow on the operated side decreased to 71·9 per cent after function-preserving surgery compared with 20·7 per cent after conventional operation. There was no tumour recurrence in either group during a mean follow-up of 24 months. ***Conclusion:*** Compared with conventional procedures, function-preserving surgery for benign parotid tumours improved cosmetic, sensory and salivary functions, and reduced the duration of surgery and operative morbidity.

***Key words:*** Treatment, Parotid, Tumor-Superficial, Total Parotidectomy, Partial

## Introduction

Tumors of the salivary glands represent 3% to 10% of all head and neck neoplasms; 75% to 85% of them originate in the parotid gland, and 70% to 80% are benign. Most involve the superficial lobe of the parotid, which accounts for 80% of the gland parenchyma (McFarland, 2011).

The most common benign tumors of the parotid gland are Pleomorphic adenoma and Warthin tumor. Pleomorphic adenomas lack a complete capsule and are surrounded by healthy gland tissue, which is compressed as they grow. They often present with very small outgrowths extending to the adjacent tissue. It is commonly believed that this histologic feature accounts for their clinical behavior, multicentricity, and recurrence over time (Snow, 2010).

The close relationship between the gland and the facial nerve, as well as the high recurrence rate, has shaped surgical techniques for parotid gland neoplasm over the years. It was not accompanied by facial nerve dissection. Removal of the tumor was incomplete, as there was tissue left behind. This procedure was widely used in parotid gland tumors for 30 years.

The treatment of parotid pleomorphic adenoma remained substantially unsuccessful until 1940, owing to a high recurrence rate (45%) and facial nerve paralysis, prompting more in-depth microscopic studies of pleomorphic adenomas and modifications of surgical techniques (Lanes, 2010).

Historically, parotid surgery evolved from surgical enucleation to superficial lobectomy or total parotidectomy with facial nerve (FN) dissection and preservation. Tumour enucleation resulted in high rates of permanent FN palsy and tumour recurrence (20–45 per cent) (McFarland, 2011;Snow, 2010).

The identification of the main trunk of the FN, followed by dissection of the nerve and removal of the superficial and/or deep lobe of the parotid gland became established as the appropriate treatment for benign and low-grade malignant lesions (Lanes, 2010; Lailey, 2013).

Although this led to a dramatic decline in local recurrence, and made permanent FN paralysis rare, it involved resection of some normal parotid tissues, leading to loss of parotid function and temporary FN paralysis. Over the past two decades, partial parotidectomy has emerged as a more conservative approach (Snow, 2010; Kumazawa, 2011; Mylonas and Angelopoulos, 2004).

In partial parotidectomy, only the tumour-bearing area of the parotid parenchyma is removed. The main trunk of the FN is identified, and the FN branch adjacent to the tumour site is dissected and preserved. This

**Corresponding Author:** Mohamed A. Foda, Health Director of Tanta Cancer Center and Head of Surgical Oncology, Egypt
E-mail: fodamohamed@hotmail.com

technique preserves the uninvolved parotid parenchyma and obviates the need for more extensive FN dissection, and has resulted in decreases in temporal FN paresis and Frey's syndrome.

These improvements have led to greater attention to other sequel of parotid surgery, including loss of sensation of the ear, cosmetic aspects and the rate of Frey's syndrome (Krouthen, 1988; Zhao *et al.,* 2011; Mylonas and Angelopoulos, 2004).

Attempts have been made to preserve the posterior branch of the greater auricular nerve (GAN), to develop a modified facelift incision for parotid surgery, and to cover the exposed parotid parenchyma with loco regional flaps (Brown and Ord, 1989; Hui, 2003; Fee, 1999; Hugo, 1995).

To date, most comparisons of surgical methods have been non-randomized retrospective reviews of institutional procedures. The present study compared postoperative complications, parotid function and recurrence rates in patients randomized to function preserving or conventional parotid surgery.

## Patients and Methods

Patients presenting with a benign parotid tumor, as assessed by fine-needle aspiration biopsy, CT and magnetic resonance imaging, were enrolled. Patients with malignant salivary gland tumours were excluded.

The patients were assigned randomly to one of two groups according to the extent of parotidectomy: 13 underwent limited partial parotidectomy (functional surgery group) and 13 underwent superficial or total parotidectomy (conventional surgery group),as showing figure 1.The study was approved by the Institutional cancer center and informed consent was obtained from each patient.


**Fig. 1:** Five patients photograph showing the preoperative benign tumor of the parotid gland a,b,c,d,and d, axial section CT showing the lesion of the parotid gland.

## Surgical techniques

In the functional surgery group, the procedure began with a preauricular and hairline incision . A skin flap was elevated in the plane superficial to the parotid fascia at the anterior border of the parotid gland.

The main trunk of the facial nerve (FN) was identified by exposing the tragal pointer and tympanomastoid suture. The overlying parotid tissue was progressively dissected free of the nerve to the first branch into upper and lower divisions of the nerve. Subsequent branches of the nerve were dissected carefully, depending on the location and size of the parotid tumor as showing in figure 2.

The tumour was removed completely, taking care to avoid capsular rupture or nerve damage, with approximately 0·5–1-cm tumour-free margins. When the tumour was located in the deep lobe of the parotid gland, the trunk and branches of the FN overlying the tumour were carefully dissected, and the tumour was removed completely, taking care to preserve the nerve and normal parotid tissues.

If the tumour was in close contact with the FN, its branches were dissected meticulously to free the tumour, taking care to avoid capsular rupture, and the deep parotid tissue adjacent to the tumour was removed separately.

All tumour-free parotid parenchyma and covering parotid fascia were preserved, and the FN branches outside the tumour-bearing area were not dissected extensively. If primary closure was possible, the remnant parotid tissues and fascia were reapproximated; for larger defects, the parotid was covered by a superiorbased sternocleidomastoid muscle flap.

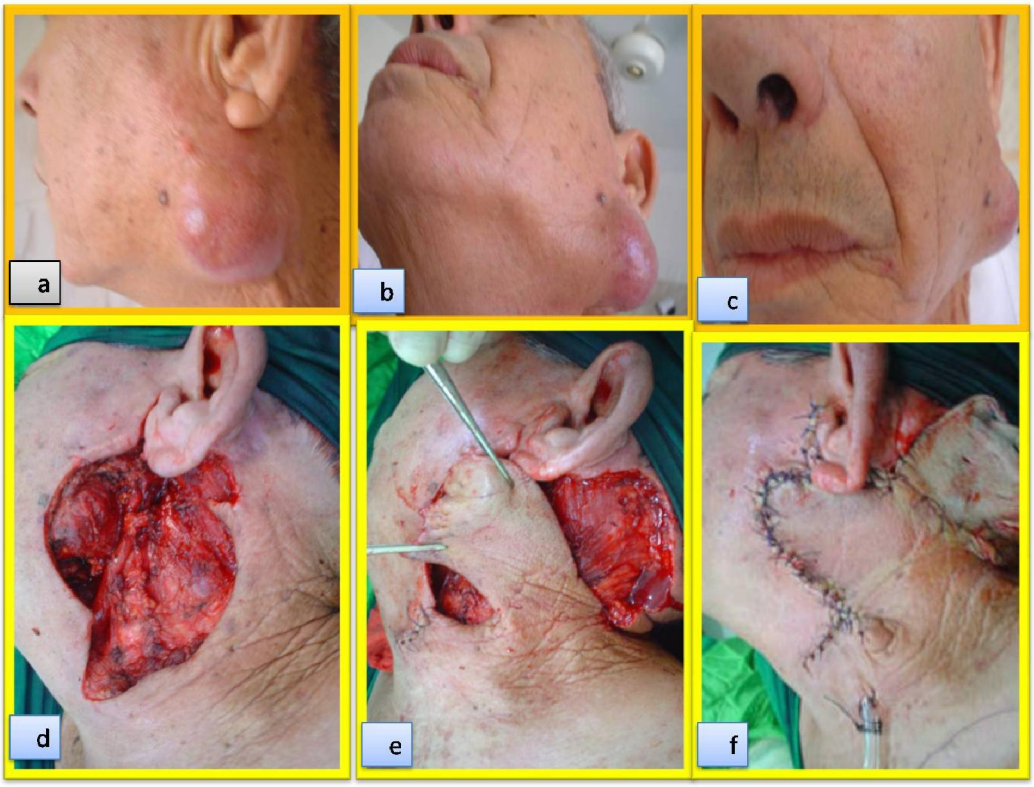


**Fig. 2:** Preoperative photograph showing the aggressive swelling of the parotid gland a, b and c, interaoperative view o showing the functional surgery resection and reconstruction by posterior auricular flap d &c, immediate postoperative after closure the defect, f.

In the other group, surgery began with a modified Blair's incision, and an S-shaped preauricular and submandibular incision. Following flap elevation, dissection was carried out in a fashion similar to that in the functional surgery group. The superficial parotid tissues were removed along with the tumour after careful dissection of all FN branches as showing in the figure 3.

When the tumour was located in the deep lobe or in both the deep and superficial lobes of the parotid gland, the entire gland was removed, taking care to preserve the FN. The exposed parotid tissues were covered by rotation of a superior-based sternocleidomastoid muscle flap. After both operations, a drain was inserted and the skin incision was closed with interrupted nylon skin sutures. The drain was usually removed 2 or 3 days after surgery. All operations were performed by the same surgeon, using surgical magnification loupes.

## Measurement of complications and function

Surgical complications and parotid gland function were monitored during the hospital stay, and 1, 3, 6, 12 and 24 months after surgery. The assessment was performed through:

*FN function*:

FN function was measured by means of the House–Brackmann system, ranging from grade I (normal function) to grade VI (complete loss of facial motor function) (Jennings and Bradley, 1999; Suen, 2005).

*Visual Analogue Scale*:

Patients rated their incision scars and facial contours 1 year after surgery using a visual analogue scale ranging from 0 to 10, with higher scores indicating greater patient satisfaction (House and Brackmann, 2011).

*Loss of Sensation*:

Loss of sensation was assessed using a wisp of cotton and a pinprick on the ear, with patients first acquainted with the stimulus by applying it to the ear on the unoperated side; each stimulus was applied at least five times.

*Statistical analysis*

Results were expressed as incidence or mean (SD). Student's *t* test was used for between-group comparisons of continuous variables, the paired *t* test was used to compare paired samples, and the $\chi 2$ test for analysis of categorical data. $P < 0{\cdot}050$ was considered statistically significant. SPSS version 12.0 for Windows was used for statistical analysis.

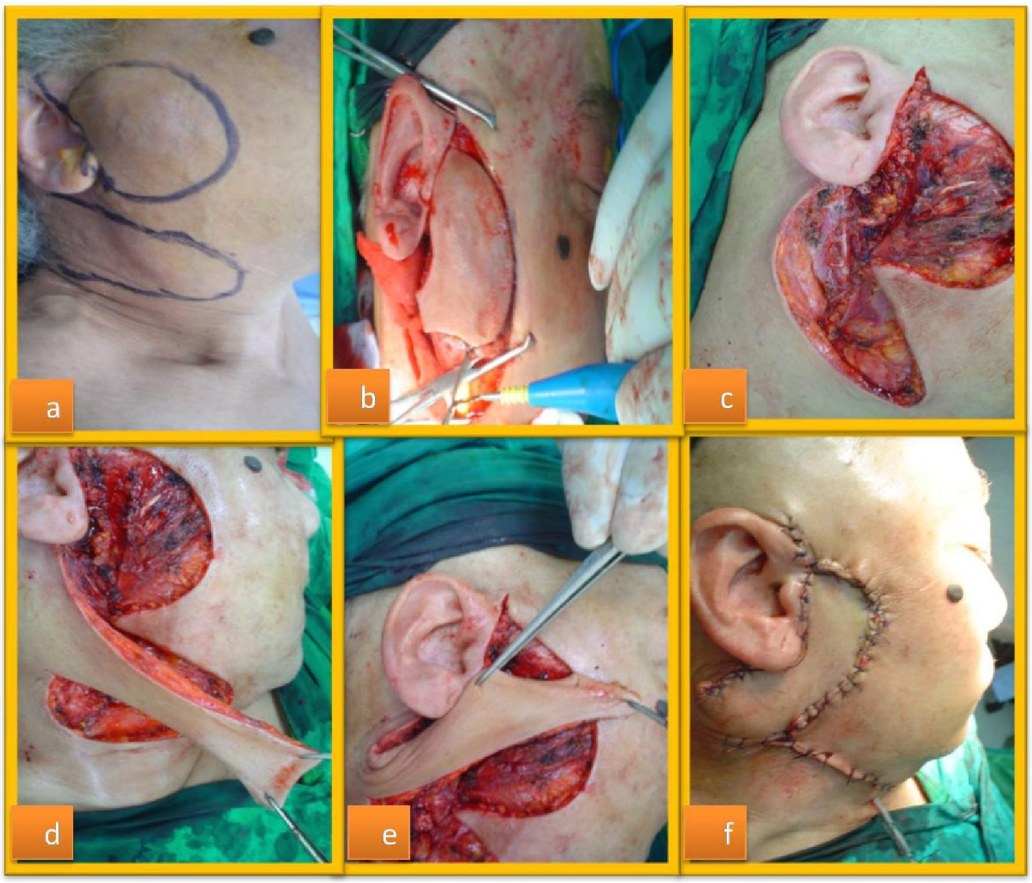


**Fig. 3:**Preoperative photograph showing the swelling of the parotid gland a, interaoperative view showing the superficial Parotidectomy resection of the lesion, b while d,e,f showing , immediate postoperative after closure the defect.

## Results

All patients in the functional surgery group had a modified facelift incision and limited partial parotidectomy; the GAN was preserved in 13 patients in the functional group, but was sacrificed in three owing to large tumour or close resection margin. In contrast, in the conventional surgery group all patients had a modified Blair incision, and removal of the superficial lobe.

Total parotidectomy 4 with sacrifice of the GAN. The size and location of the tumour, and proximity to the FN were comparable in the two groups. None of the patients had a positive resection margin. Two patients in the conventional surgery group had small capsular ruptures, which were immediately sucked out and irrigated during surgery.

The mean duration of operation was significantly shorter for function-preserving surgery than conventional operation ($P < 0{\cdot}001$).

The overall complication rate was significantly higher after conventional than functional surgery ($P < 0{\cdot}05$). four of 13patients (33% per cent) in the functional group had early complications *versus* 13 of 13 patients (100 per cent) in the conventional group ($P < 0{\cdot}001$).

Four of 13 patients in the functional group had late (1 year) complications *versus* 4 of 13 patients in the conventional group ($P = 0{\cdot}007$). Auricular hypoesthesia was detected in 64·4 per cent) of the 25 patients, particularly after the GAN had been sacrificed. Most patients had recovered sensation by 1 year after surgery, although it remained lost in one patient after functional surgery and eight after conventional surgery ($P = 0{\cdot}028$).

Temporary facial weakness was observed in 22·8 per cent of 26 patients overall, and was significantly more common after a conventional procedure (P = 0·011). Hypertrophic scars at the incision sites occurred in four patients in each group, but were commonly masked by the ear and hair in the functional surgery group.

## Discussion

Results of the present study showed that, both surgical techniques were effective, with no tumour recurrence during a mean follow-up of 4 years. This accords with previous studies, in which local recurrence was very rare suggesting that prolonged follow up is unnecessary .This was in agreement with (McFarland ,2011).

The current work may lend support to previous thought that, Pleomorphic adenomas can invade or project beyond their macroscopic boundaries into normal tissues. Tumour recurrence is thought to arise from these small projections, which may be left behind at operation and may explain the high recurrence rate (20–45 per cent) when enucleation was the procedure of choice. This was in full agreement with (Snow 2010), they found that the Pleomorphic adenomas can invade or project beyond their macroscopic boundaries into normal tissues. (Lailey 2011).

It has been postulated that, the removal of normal parotid tissue affected salivary function in all patients who underwent superficial or total parotidectomy. On the contrary, the current study claimed that, the assessed parotid salivary function in 7 patients who underwent superficial or total parotidectomy and found that, although none complained of dry mouth after surgery, (Lanes 2010).

An interesting point, in the present study the parotid salivary function decreased after both functional and conventional surgery, although it recovered to about 70 per cent of preoperative values after functional surgery, but not after superficial or total parotidectomy.

Not surprisingly, analysis of the results showed that, the superficial lobe constitutes about 80 per cent of parotid volume and so removal of the entire superficial lobe is associated with significant loss of glandular function. This was concurred with the study performed by Kumazawa (2012)

## Conclusion:

The present study provided further evidence that limited partial parotidectomy for benign parotid tumours can preserve salivary function. The currently recommended procedure of superficial lobectomy with FN preservation for benign tumours is not a pure *en bloc* resection in most cases.

## References

Brown, J.S., R.A. Ord, 1989. Preserving the great auricular nerve in parotid surgery. Br J Oral Maxillofac Surg., 27: 459–466.

Fee, W.E. Jr., 1999. Modified facelift incision for parotidectomy. J Laryngol Otol., 108: 574–578.

House, J.W., D.E. Brackmann, 2011. Facial nerve grading system. Otolaryngol Head Neck Surg., 93: 146–147.

Hugo, N.E., 1995. Frey's syndrome: prevention with temporoparietal fascial flap interposition. Ann Plast Surg., 34: 292–296.

Hui, Y, 2003. A prospective controlled double-blind trial of great auricular nerve preservation at parotidectomy. Am J Surg., 185:574–579.

Jennings, C.R., P.J. Bradley, 1999. Frey's syndrome following parotidectomy. Clin Otolaryngol Allied Sci., 24: 365–368.

Krouthen, B., 1988. Superficial parotidectomy or limited excision? J Laryngol Otol., 102: 603–605.

Kumazawa, T., 2011. The usefulness of partial parotidectomy. A retrospective study of 306 cases. Acta Otolaryngol Suppl., 500: 113–116.

Lailey, H., 2013. Treatment of tumours of the parotid gland with special reference to total parotidectomy. Br J Surg., 28: 337–346.

Lanes, R.M.,2010. The treatment of tumours of the salivary glands by radical excision. Can Med Assoc J., 43: 554–559.

McFarland, J., 2011. Hundred mixed tumors of the salivary glands. Br J Surg., 63: 457–468.
Mylonas, A.I., A.P. Angelopoulos,2004.Superficial parotidectomy: technical modifications. J Craniomaxillofac Surg., 32: 350–353.
Snow, G.B., 2010. Surgical management of 246 previously untreated pleomorphic adenomas of parotid gland. Br J Surg., 84: 399–403.
Suen, J.Y., 2005. Benign neoplasms of the salivary glands. In Otolaryngology Head and Neck Surgery Review (4th edn), Cummings CW, Flint PW, Haughey BH, (eds). Mosby: Philadelphia, 1348–1377.
Zhao, K., D. Y.Qi, , LM.Wang, 2011. Functional superficial parotidectomy. J Oral Maxillofac Surg., 52: 1038–1041.