

## Central Proliferative Diabetic Retinopathy; Evaluation and Management

**Hazem M. Azab, MD**

*Giza Memorial Institute, Ophthalmology Teaching Hospital, Giza, Egypt.  
E-mail: hazemazab2@gmail.com*

**Maged Adly Naguib, MD**

*Giza Memorial Institute, Ophthalmology Teaching Hospital, Giza, Egypt.  
E-mail: drmagedadly@yahoo.com*

**Alaa Attia MD**

*Giza Memorial Institute, Ophthalmology Teaching Hospital, Giza, Egypt.  
E-mail: AliIbrahim@yahoo.com*

**Mohamed Elkasaby, MD**

*Faculty of Medicine, Al - Azhar University, Cairo, Egypt  
E-mail: AliIbrahim@yahoo.com*

**Ali Hendy El Ghamdi MD**

*Faculty of Medicine, Al Baha University, Al Baha, Saudi Arabia  
E-mail: Abohani2020@hotmail.com*

**Mostafa Mahmoud Darwish MD**

*Faculty of Medicine, Al - Azhar University, Egypt*

---

*Received: 20 February 2017 / Accepted: 22 March 2017 / Publication date: 23 March 2017*

### ABSTRACT

**Aims:** to evaluate the outcome of central proliferative diabetic retinopathy after pars plana vitrectomy. **Method:** This prospective, observation randomized study included 90 eyes of 60 patients with central proliferative diabetic retinopathy underwent for pars plana vitrectomy by a three vitreoretinal surgeons. Patients were seen at second postoperative day then one week then two weeks and 1, 3, 6, 12 months after surgery. Clinical outcome were recorded every visit. **Results :** Ninety eyes of 60 patients with severe PDR involved macula and central retina was recorded .30 patients out of 60 patients females (50%) while 30 patients out of 60 were male (50%) , age ranging from 20-70 years , 30 (50%) patients out of 60 had bilateral PDR,30 (50%) patients out of 60 unilateral PDR (55.5%) type I DM and (44.4%)patients had type II .

**Key words:** Proliferative diabetic retinopathy, triamcinolone , laser pan retinal endophotocoagulation , haemorrhage, fibrovascular proliferation-tractional retinal detachment, epi retinal fibrovascular proliferations, 23gauge ,silicone oil.

---

### Introduction

Diabetic retinopathy (DR) is one of the most common complications of diabetes affecting millions of working adults worldwide, in which the retina, becomes progressively damaged, leading to vision loss and blindness. (Ismail-Beigi *et al.*, 2010).

Proliferative diabetic retinopathy (PDR) was commonly developed in central and peripheral retina or both. Central PDR was secondary to ischaemic proliferative processes and with neovascularization of disc (NVD) , that is commonly showed in diabetic patients type I, while peripheral PDR, was showed in neglected vitreous hameorrhage (vit hge) and with neovascularization elsewhere (NVE) , that is commonly showed in patients type II. Tractional retinal detachment (TRD) involving or threatening the macula is one of the primary indication for vitrectomy in diabetic retinopathy (D.R.) (Smiddy and Flynn, 2010). Anatomical and functional results were recorded in this study.

---

**Corresponding Author:** Maged Adly Naguib, Giza Memorial Institute, Ophthalmology Teaching Hospital, Giza, Egypt. E-mail: drmagedadly@yahoo.com

## **Patients and Methods**

Ninety eyes of 60 patients with severe PDR involving macula and central retina was recorded. 30 patients out of 60 patients females (50%) while 30 patients out of 60 were male (50%), age ranging from 20-70 years, 30 (50%) patients out of 60 had bilateral PDR, 30 (50%) patients out of 60 unilateral PDR (55.5%) type I DM and (44.4%) patients had type II, with duration of diabetes from  $\leq 10$  years to 21 (mean 17.41%). All patients were subjected to full preoperative ophthalmologic assessment including: history taking, clinical examination and some investigations.

### **Full patients History with special stress on:**

Age of patients, onset of diabetes (discovery) and duration of diabetes from discovery until time of inclusion, positive family history, type of diabetic patients (type I and type II) associated systemic disease associated systemic complication to diabetes mellitus.

### **Ophthalmological Examination**

Best corrected visual acuity (BCVA), it was measured using Landolt's chart broken rings and hand motion and counting fingers were done if the patients cannot see the chart. Record of the best corrected visual acuity (BCVA). It was measured using Snellen visual acuity charts and it was converted to the decimal system to allow statistical analysis as shown in table (1).

Slit lamp examination with special focus on: presence of any corneal opacities that may affect vision or prevent laser delivery, presence of early rubeosis before pupillary dilatation and gonioscopy was recommended to exclude neovascular glaucoma. Presence of any lens opacity, intraocular tension (I.O.P) measurement by using applanation tonometry after application of surface anaesthetic eye drops. Fundus examination was done after maximum pupillary dilatation by a combination of Tropicamide 1% eye drops and phenylephrine 2.5% drops. Using both slit lamp biomicroscopy with non contact lens +90 D Volk or wide field lens +160D lens and indirect ophthalmoscopy using a +20 D a biconvex spheric lens was used to examine the vitreous for the presence of hemorrhage, membranes and extent of the posterior detachment (PVD). The retina was evaluated for the presence and extent of neovascularization, pre and epiretinal fibrovascular membranes, retinal and macular traction or detachment and extent of laser photocoagulation if present.

B-scan ultrasound was done for patients with severe vitreous hemorrhage, extension with tractional proliferative tissues and fundus details cannot be evaluated. Fundus fluorescein angiography (FFA), ocular coherence tomography (OCT) for assessment anatomical and functional evaluation.

Medical and laboratory examination as complete general examination, fasting and two hours post prandial blood sugar, renal and hepatic functional tests and ECG was done.

Pre operative topical Cycloplegic and a combination of antibiotic/steroid preparation were used. Preoperative data included: age, general medical condition, affected eye, ocular diagnosis, visual acuity, type and severity of preexisting lens changes, and status of the fellow eye. Intra operative data recorded included in advertent lens damage, iatrogenic breaks, hemorrhage and other operative complication. Operative procedures, 20 and 23 gauge vitrectomy was done in all cases, with using a wide angle vitrectomy system (BIOM lens) in a standardized procedure. Ringer lactate and balanced salt solution (B.S.S.) was used as the infusion fluid, phacovitrectomy was done in dense cataract, anterior vitrectomy behind the lens was removed meticulously in phakic eyes, removing the central vitreous gel, posterior vitrectomy; taut posterior hyaloids face extending from the anterior vitreous base to the abnormal posterior retinal adhesion is circumcised, relieving anteroposterior tractional forces, shaving program for proliferative tissue rolling main vascular arcades and proliferative tissue tint obscured macular area. Epipapillary neovascular proliferations were avoided to remove.

A triamcinolone aqueous suspension (Kenacort-A; SmithKline Beecham Egypt L.L.C. An affiliated co. to GlaxoSmithKline,) was left standing for 30 seconds and the vehicle of triamcinolone acetonide was discarded. The remaining triamcinolone acetonide (40 mg) suspension was mixed with 5 ml balanced salt solution and then was used for the following procedure as a triamcinolone suspension:

Posterior hyaloid separation: A core vitrectomy was performed (using Accurus and constellation. (Alcon Laboratories, Inc, USA) vitrectomy machine with the following parameters and accessories:

Light source (built in accurus vitrectomy machine) connected to endoillumination probe, which may be panoramic or focal type.

Cutting rate from 1000 to 2500 cycles /second using disposable cutter.

Aspiration pressure from 100 to 300 mmHg. Infusion bottle of BSS at height at 75+/- 10 cm. Removal of clotted blood, release of epiretinal membranes and tangential traction is attacked by sectioning preretinal membranes with vitreous scissors. Perfluorocarbene liquid (PFCL) was used in most cases to flatten an RD that developed when a tight vitreoretinal adhesion was loosened to facilitate effective endolaser. Retinal tamponade was achieved by injection of silicone oil (5000Cs) controlled by IOP which measured digitally during operation. Endodiathermy was used as necessary to control bleeding. Diode laser pan retinal endophotocoagulation was done with wave length 810 NM diode laser. Removal of the 23 gauge canula with compression and massage for 15 second to prevent escape of fluid, eye patching after topical corticosteroids and antibiotics. All cases were operated by three surgeons Dr. Hazem azab Dr Maged Adly Dr Alla Attia between January 2015 and September 2016. in Giza memorial institute of ophthalmic research.

### **Post operative care:**

All patients was discharged within the first post operative day and the following medication was given, hypoglycaemic drugs according to the previous schedule, systemic antibiotics and combined steroid, antibiotic eye drops with gradually drawn over the first postoperative one month and half, topical Cycloplegic eye drops 3 times for one week.

### **Post operative follow up:**

All patients were followed up after one day, one week, two weeks, one months and three months, six months and yearly. Every follow up visit the following was done: best corrected visual acuity, slit lamp examination for corneal oedema abrasion ulcer, presence for lens complications as cataract, development or regression of rubeosis iridis, IOP was measured digitally or by applanation tonometer, fundus examination, presence of complication.

### **Statistical Analysis:**

All data were collected retrospectively, preoperative diagnosis, intraoperative data and postoperative data were recorded. The follow-up interval ranged from one day up to year. All data were collected and entered into a database for analysis. Statistical analysis. IBM (International Business Machines) Statistical Package for the Social Sciences (SPSS) (V. 19.0, IBM Corporation, USA, 2010) will be used for data analysis. Data will be expressed as Mean  $\pm$ SD for quantitative parametric measures in addition to Median Percentiles for quantitative non-parametric measures and both number and percentage for categorized data. P value of  $<0.05$  was considered significant. The data graph 2.90h for MS Office XP was used for analysis of refractive and other visual outcome data and to generate standard graphs.

### **Results**

Ninety eyes of 60 patients with severe PDR involved macula and central retina was recorded. 30 patients out of 60 patients females (50%) while 30 patients out of 60 were male (50%), age ranging from 20-70 years, 30 (50%) patients out of 60 had bilateral PDR, 30 (50%) patients out of 60 unilateral PDR (55.5%) type I DM and (44.4%) patients had type II with duration of diabetes from  $\leq 10$  years to 21 (mean 17.41%). All patients were subjected to full preoperative ophthalmologic assessment including: history taking, clinical examination and some investigations:

The visual acuity improve in 52 eyes (58.2%) at 6 month follow up in patient with controlled or diminished IOP

\*Haemorrhage: and tractional retinal detachment: improved in 56.2 % and fibrovascular proliferation is lessened by 33.3 %

Complications as lens touch cataract, post operatively haemorrhage and increase IOP, progressive ischaemia .Where V/A diminished in 6 eyes (28.6) , improved in 11 eyes (52.4) and still constant in 4(19.0) with previous complications.

Table (1): Distribution of the age and duration of diabetes mellitus among the study group.

All patients suffered diabetes mellitus with duration of diabetes ranges between  $\leq 10$  years and 21 years with mean standard deviation  $17.41 \pm 4.9$ .

See tables from 2 to 5

These tables shows the incidence of both type of diabetes mellitus type I and type II with associated relative diseases as renal impairment

See table 6

Preoperative VA could be an indicator of postoperative VA at the the 2<sup>nd</sup> week and the 1<sup>st</sup> month , and the rate of improvement in VA at one and six months of follow up.

See tables from 7 to 16

Table (16 and 17) shows non significant relation between changes of IOP and the presence of complications as haemorrhages and cataract.

**Table 1:** Distribution of the age and duration of diabetes mellitus among the study group.

	Range	Mean $\pm$ SD
Age	22- 70.0	54.3 $\pm$ 9.6
Duration	10.00 -21.0	17.41 $\pm$ 4.9(3.0-30.0)

**Table 2:** Distribution of the age among the study patients in relation to the different preoperative indications.

	Age					ANOVA		
	Range			Mean	$\pm$	SD	F	P-value
Vitreous hemorrhage with FVP and TRD	25.	-	59.	46.1	$\pm$	12.206	3.678	0.021
Vitreous hemorrhagewith FVP	24.	-	61.	44.0	$\pm$	12.555		
Dense persistent vitreous hemorrhage.	50	-	68.	57.6	$\pm$	7.127		
Persistent macular edema	55.	-	65.	59.6	$\pm$	3.647		

\*Haemorrhage: hge . \*Fibrovascular proliferation: FVP, \*Tractional retinal detachment: TRD.

**Table 3:** Mean Percentage in VA In Relation To the Diagnosis the patients is presented with:

Status	Median (IQ Range)	P value
Haemorrhgae		
Absent	56.2(75.0 – 0.0)	NS
Present	33.3(102.6 – - 1.5)	
RD		
Absent	56.2 (75.0 – 0.0)	NS
Present	25.0(87.5 – -20.6)	
Retinal membrane		
Absent	33.3(100.0 – -2.9)	NS
	11.04(137.5 – 0.0)	

**Table 4 :** Average Percentage Change in Visual Acuity at the 1<sup>st</sup>& 6<sup>th</sup> month Post operatively

Median (IQ Range)	
1 <sup>st</sup> Month	9.8 (60 -< -13.5%>
6 <sup>th</sup> Month	33.3(100%-0.0%)

The (-) sign denotes percentage diminution in visual acuity , visual acuity improved form 9.8 (60 -< -13.5%> at one month to 33.3(100%-0.0%) at 6<sup>th</sup> months follow up.

**Table 5:** Changes in VA at the end of follow up in relation to Different Age Groups, Sex, and Type of diabetes, Duration of Diabetes and presence of associated related diseases:

Status	Constant	Improved	Diminished	Pvalue
<b>Age group</b>				
< 50 yrs	5	12(50.0%)	7(29.2%)	NS
50–	4	31(72.1%)	9(18.6%)	
60–	4(25.0)	7(43.8%)	5(31.3%)	
70+	1(16.9%)	4(66.7%)	1(16.7%)	
<b>Sex</b>				
Female	9(18.4%)	28(57.1%)	12(24.5%)	NS
Male	5(12.5%)	26(65.0%)	9(22.5%)	
<b>Type of Diabetes</b>				
IDDM	2(13.3%)	7(46.7%)	6(40.0%)	0.26 NS
NIDDM	12(16.2%)	47(63.5%)	16(20.3%)	
<b>Duration of Diabetes</b>				
≤ 10 yrs	1(10.%)	9(90.0%)	—	NS
11–	5(20.0%)	14(56.0%)	6(24.0%)	
16–	8(19.0%)	23(54.8%)	14(26.2%)	
21+	—	7(70.0%)	3(30.0%)	
<b>Associated Related Diseases</b>				
Present	4(17.4%)	16(69.6%)	3(13.0%)	NS
Absent	10(15.2%)	38(57.6%)	18(27.0%)	

**Table 6:** Correlation of preoperative VA to postoperative VA on 1<sup>st</sup> day, 2<sup>nd</sup> day, 1<sup>st</sup> month and 6<sup>th</sup> month and changes in VA at one month and 6<sup>th</sup> month follow up from preoperative VA status .

	$\sqrt{sp}$	P value
VA at 1 <sup>st</sup> day	0.045	NS
VA at 2 <sup>nd</sup> day	0.374	<0.001 HS
VA at 1 <sup>st</sup> month	0.249	0.018 sig
VA at 6 <sup>th</sup> month	0.113	NS
Change at 1 month	0.668	<0.001 HS
Change at 6 month	0.580	<0.001 HS

**Table 7:** Percentage Changes in visual Acuity in Relations to Different Age, Sex, Type of diabetes and Presence of Associated related Diseases.

Status	Median (IQ Rnage)	Pvalue
<b>Age group</b>		
< 50 yrs	12(72.9 – -17.0)	0.51 NS
50–	49.5(142.2–0.)	
60–	0.0(98.6– -14.0)	
70+	50.0(154.2– -15.5)	
<b>Sex</b>		
Female	33.3(100.0 – 0.0)	0.05 sig
Male	18.7(114.6– -6.2)	
<b>Type of Diabetes</b>		
IDDM	0.0 (33.3– -33.3)	0.09 NS
NIDDM	58(112.6– 0.0)	
<b>Duration of Diabetes</b>		
≤ 10 yrs	66.7(162.5– 32.9)	NS
11–	25.0(125.0– -6.2)	
16–	33.3(100.0 – - 6.3)	

21+	42.7(200.0 – -45.8)	
Associated Related Diseases		
Present	66.7(100.0– 0.0)	0.05 Sig
Absent	21.9( 102.6 – -9.0)	

**Table 8:** Average Percentage Changes in VA at the 6<sup>th</sup> month in relation to Past History of Laser Exposure and whether a signaled or both eyes are operated upon.

Status	Median (IQ Range)	P value
PH of laser	60.0(116.7– 0.0)	NS
Relevant		
Irrelevant	11.1(100.0– - 2.9)	
Uinl/ bilateral		NS
Unilateral	33.3(100.0– -5.9)	
Bilateral	38.1(102.6– o.o)	

*This table shows patient with past history of argon laser photocoagulation and its effect on visual acuity post operatively.*

**Table 9:** Average Percentage Changes in VA in Relation to Operative Details Performed

Status	Median (IQ Rnge)	P value
PFC		
Done	60.0(109.4 – 0.0)	NS
Not	21.9(98.6 – - 11.8)	
Endolaser		
Done	49.5 (107.9 – 0.0)	0.01 sig
Not	-33.3(9.4 – -81.0)	
Endodiathermy		
Done	10.8(150.0 – 0.0)	NS
Not	33.3(100.0 – 0.0)	

**Table 10:** Changes in VA in Relation To Incidence of Complications

Status	Complication		P value
	Present n(%)	Absent n(%)	
Diminished	6(28.6)	16(22.11)	NS
Constant	4(19.0)	10(14.1)	
Improved	11(52.4)	43(63.2)	

*Complications as lens touch cataract, post operatively haemorrhage and increase IOP, progressive ischaemia .Where V/A diminshed in 6 eyes (28.6) , improved in 11 eyes (52.4) and still constant in 4(19.0) with previous complications.*

**Table 11:** Average Percentage Changes in VA in Relation to Incidence of Complications

Median (IQ Range)		
Complications		P value
Present	3.3 (63.3 - -10-8)	0.11NS
Absent	63.3(118.7-0.0)	

**Table 12 :** Mean Percentage Changes in VA in relation To Incidence of Complications

Status	Median (IQ Range)	P value
Cataract		
+ve	33.3( 75.0– 0.0)	NS
-ve	38.1 (112.6 – -1.9)	
Haemorrhage		
+ve	16.7(66.7– 0.0)	

-ve	38.1(102.6 – -1.5)	NS
Increase IOP		
+ve	16.7(66.7 – -14.5)	0.07 NS
-ve	58.9(116.7 – 0.0)	

**Table 13:** Incidence of Postoperative Cataract in relation to Age groups, Sex , Type and Duration of Diabetes and associated related Diseases :

Status	Incident Cataract		Pvalue
Age group	Number	%	
< 50 yrs	5	25.0	NS
50–	8	33.3	
60–	2	33.3	
70+	–	0.0	
Sex			
Female	11	29.7	NS
Male	4	20.0	
Type of Diabetes			
IDDM	4	28.6	NS
NIDDM	11	25.6	
Duration of Diabetes			
≤ 10 yrs	–	0.0	0.07NS
11–	7	46.7	
16–	5	18.5	
21+	3	37.5	
Associated Related Diseases			
Present	4	40.0	NS
Absent	11	23.4	

**Table 14:** Changes in IOP at 6 months follow up in relation to Changes in VA at one month & 6 months follow up.

Duration	Increase	Decreased/ constant	P value
1 <sup>st</sup> month	N(%)	N (%)	
Diminished	9(36.0)	16 (64.0)	NS
Constant	4(33.3)	8(66.70)	
Improved	16(30.2)	37(69.8)	
6 <sup>th</sup> month			
Diminished	10(47.6)	12(52.4)	NS
Constant	4(28.6)	10(71.4)	
Improved	15(27.8)	39(72.2)	

*The V/A improve in 39(72.2) eyes at 6 month follow up in patient with controlled or diminished IOP*

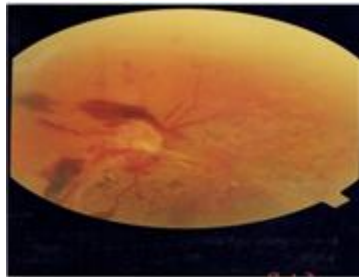
**Table 15 :**Relation of changes in IOP at 6<sup>th</sup> month follow up in relation to some presentations

Status	IOP		P value
	Increased N(%)	Constant /diminished N (%)	
Haemorrhgae			
Absent	4(26.70)	11(73.3)	NS
Present	25(33.3)	50(66.7)	
RD			
Absent	20(29.0)	49(71.0)	NS
Present	9(42.9)	12(57.1)	
Retinal membrane			
Absent	27(32.9)	55(67.1)	

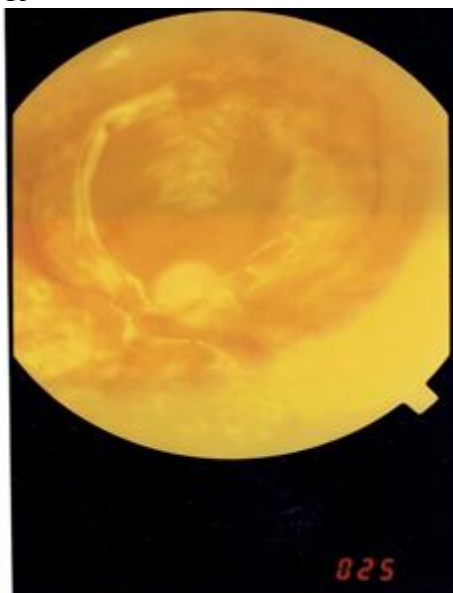
Present	2(25.0)	6(75.0)	NS
---------	---------	---------	----

**Table 16 :** Changes in IOP at 6 months follow up in relation to Incidence of Complications

Status	IOP		P value
	Increased N(%)	Constant /diminished N (%)	
Complications			
Present	7(33.3)	14(66.7)	NS
Absent	14(21.9)	55(69.7)	
Haemorrhage			
Present	2(28.6)	5(71.0)	NS
Absent	27(32.5)	56(67.5)	
Cataract			
Present	10(66.9)	7(87.5)	NS
Absent	8(34.1)	54(65.9)	

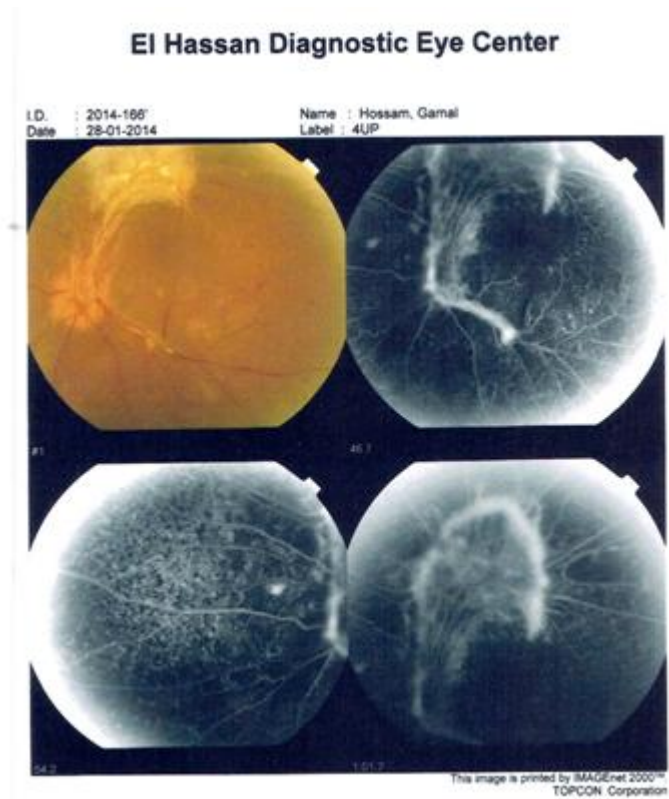


**Fig. 1:** Left eye with central PDR

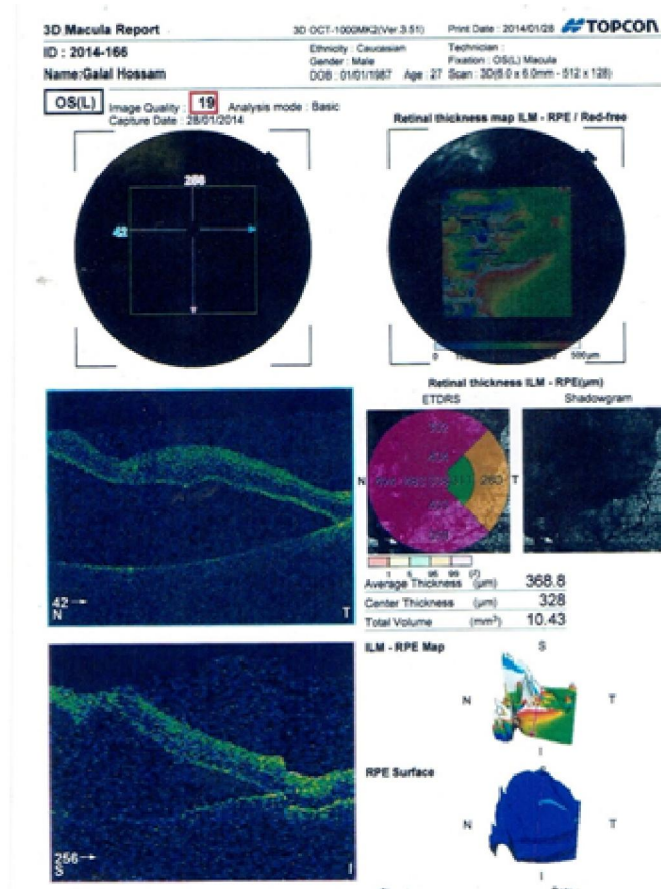


**Fig. 2:** Preoperatively central PDR with TRD

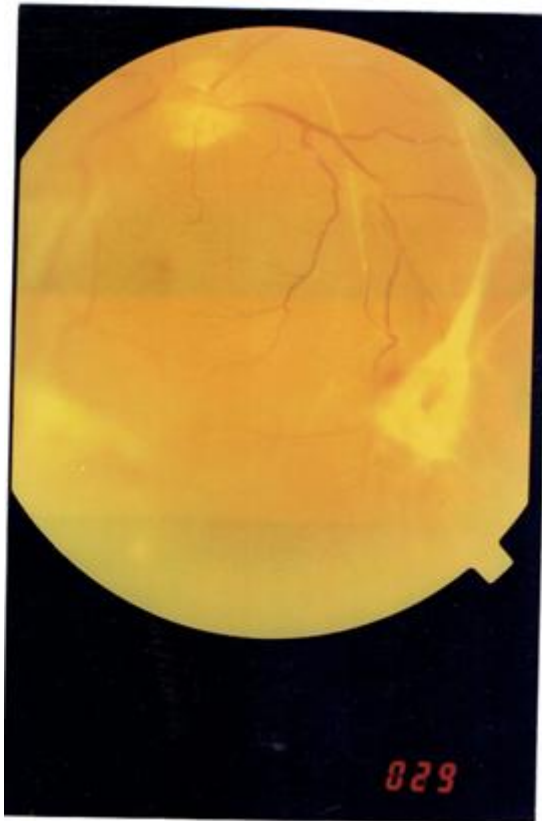




**Fig. 3:** Colored and FFA post operatively shows release of traction



**Fig. 4:**Pre-operative OCT for patients with macular detachment , central thickness 328 microne



**Fig. 5:** Postoperatively after removal all traction

## **Discussion**

Retinopathy is the most feared complication of diabetes, compromising quality of life in most sufferers. Almost all patients with type 1 diabetes will develop retinopathy over a 15- to 20-year period, and approximately 20–30% will advance to the blinding stage of the disease. Greater than 60% of patients with type II diabetes will have retinopathy. With the global epidemic of type II diabetes, this predicament is set to worsen as over 360 million people are projected to suffer from diabetes and its complications by 2030. Vision loss from diabetes is due to a number of factors, including hemorrhage from new and poorly formed blood vessels, retinal detachment due to contraction of deposited fibrous tissue, and neovascular glaucoma resulting in an increase in intraocular pressure. Diabetic macular edema is now the principal cause of vision loss in diabetes and involves leakage from a disrupted blood-retinal barrier (Wilkinson-Berka and Miller, 2008).

Progressive macular traction is characterized by partial vitreous detachment with vitreoretinal traction along the temporal arcades and the optic nerve head. It causes retinal traction extending through the fovea and, if progression is allowed, it will lead to macular heterotopia or to tractional RD of the macula. Several authors have suggested that these changes are features of proliferative diabetic retinopathy (Pastor, 2011).

The indications for surgical intervention in patients with diabetic retinopathy are broad, the diabetic vitrectomy study (DRVS) established the role of early surgery for patients with type I diabetes and vitreous haemorrhage (Dauglas *et al.*, 2003; Ming *et al.*, 2009).

TRD involving or threatening the macula is one of the primary indications for vitrectomy in DR. The visual benefit of surgery for TRD is variable and depends on the degree of the macular function. Severe active fibrovascular proliferation in spite of maximum P.D.R. and also an indication for operative intervention (Mianami *et al.*, 2003).

In our study, we focused on anatomical and functional results after vitreoretinal surgery in advanced PDR involving the macula and central retina following activation of fibrovascular arcades, which ended with the formation of membranes that tend to obscure the macular area (Fig. 1-2), the goal of surgery summarized in the shaving and delimitation of proliferative and fibrovascular proliferative membranes as far as possible.

to open visual pathway in front of macular area, relief tractional on retinal surface with reattachment of retina and stabilized by heavy internal tamponade like silicone oil. Third goal to washing and lavage the internal vitreal media from the proliferative factors to inhibit the activation of proliferative cycle. The main goal of surgery in these cases were increase life spane of vision for long time as possible as, because most like cases usually were lost vision within short time secondary to progress of activations proliferative cycle and ischemic changes

### **Visual acuity:**

In our study, the range of preoperative best corrected visual acuity ranged from 0.005 to 0.5 because we had a variety of preoperative indications of surgery ranging from cases of dense vitreous hemorrhage (vision from HM to CF) to cases with mild vitreous hemorrhage and FVP and cases of tractional macular edema who had a relatively good vision up to 0.5 (20/40).

All too often, final visual acuity is limited despite successful achievement of the surgical and anatomic objectives. This outcome is usually attributable to generalized retinal ischemia, which may be evident as attenuated arterioles, capillary non perfusion, and retinal thinning (featureless) (Smiddy and Flynn, 2010).

### **Type of diabetes mellitus:**

In this study the total number of eyes of patients with type I diabetes was 15 (16.6%) and that of type II was 75 (83.3%).

Of concern, there is epidemiological evidence that retinopathy begins to develop at least 7 years before the clinical diagnosis of NIDDM is made. Patients with NIDDM are at significantly high risk for diabetic retinopathy. Usually central PDR was developed in type I D.M. In our study, recurrent activation of proliferative cycle and progresses of ischemic changes were statistically high in type- I D.M. than type- II.

### **Duration of Diabetes Mellitus:**

The mean standard deviation of diabetes  $17.41 \pm 4.9$  (3.0-30.0) (ranging from  $\leq 10$  to +21 years) since discovery of the disease.

The strongest predictor for the prevalence of retinopathy in persons with type I and type II diabetes is the duration of diabetes. In the younger onset group in the WESDR, the prevalence of any retinopathy was 8% among participants with diabetes duration of 3 years, 25% for 5 years, 60% for 10 years, and 80% for 15 years. The prevalence of proliferative retinopathy was 0% for those with diabetes duration of 3 years, increasing to 25% for 15 years (Klein *et al.*, 1984).

In our study the average duration of diabetes is relatively long ranging from  $\leq 10$  to +21 years duration because all patients in the study had been diagnosed to have proliferative diabetic retinopathy and then all patients had panretinal photocoagulation after that we followed the patients for a time to diagnose progression in spite of retinal laser photocoagulation.

9.8 (60 < -13.5% > raising to 33.3(100%-0.0%) at 6<sup>th</sup> months shows average changes in visual acuity at one and six months 22 (24.4%) eyes with recession of anatomical and functional results secondary to progress of ischameic changes and diabetic blood insufficiency or with activation of proliferative cycle and recurrent proliferative and fibrovascular tissue formation with recurrent TRD.68eyes(75.6 %) eyes with preserved vision due to established vascular supply secondary control of DM, hypertension and other factors which recorded as 13(14.4%) with type I and 63(70.0%) type II. Systemic blood sugar, hypertension and lipid controlled should be optimized prior to surgical intervention. In this study follow up period extended up to one years. Vitreoretinal surgery is difficult to perform with high rate of anatomical reduction but a poor functional recovery rate for a late PDR with macular area or central PDR (Dugals *et al.*, 2003). In case of severe PDR with TRD not involved macula, its best to defer vitrectomy unless definite progression that threatens the vascular center in documented (Avitabile *et al.*, 2011). This study was coincided with the study done by Smiddy and Flynn, (2010), study of vitrectomy for complication of PDR was the eyes with better vision in 68(32%) patients at the conclusion of 213 patients with severe PDR (Smiddy and Flynn, 2010).

Initial management with PP lensectomy and vitrectomy with silicone oil tamponade can achieve favorable anatomic and visual outcomes in selected patients with cataract and TRD involving macula associated with severe PDR. The number of study eyes with as best corrected vision of 6 over 60 or better increased from 52 (57.7%) at one month to 53 eyes (58.8%) at 6 months up to one year (Mianami *et al.*, 2003).

### **Postoperative glaucoma:**

Glaucoma was described by many authors in varying percentages (from 1.7% to 8%) after vitrectomy (Tachi and Ogino, 1996; Yang, 2000).

Transient increase in IOP was realized in 9 eyes (10.8%). Five eyes secondary to escape of silicone oil to anterior chamber. Medical treatment in the form of IOP lowering drops was successful in managing those cases without need for glaucoma filtering surgery.

### **Associated medical risk factors**

Number of eyes of patients with associated systemic diseases as diabetic nephropathy, hypertension and liver impairment was 23 eyes (25.5%). Hypertension has long been hypothesized to be a risk factor for retinopathy in patients with diabetes (Rassam *et al.*, 1995).

Data from epidemiological studies and clinical trials support clinical guidelines to control elevated blood pressure in patients with type II diabetes to reduce visual loss from retinopathy, as well as morbidity and mortality from cardiovascular diseases (Wong *et al.*, 2010).

### **3- Cataract formation:**

Pendergast *et al.* (2000) the most common postoperative complication after vitrectomy was cataract formation, which occurred in 24 (63.2%) of the 38 phakic eyes.

In our study, cataract occurred in 11 eyes out of 57 clear lens preoperatively became cataractous at 6 month post operative follow up with silicone oil internal tamponade. The incidence of postoperative cataract formation in our study is comparable to the previous results of other researchers.

### **Intraoperative and postoperative vitreous hemorrhage**

Postoperative vitreous hemorrhage occurs to some degree in 7 (7.7) cases, Harbour *et al.*, (1996), postoperative vitreous hemorrhage developed in 1 (10%) of 10 eyes after vitrectomy and surgical removal of the posterior hyaloid but resolved spontaneously over a two month period. In Yamamoto *et al.*, (2010) postoperative vitreous hemorrhage occurred only in 1 of 65 (1.5%) eyes.

In our study all Intra operative hemorrhage was controllable and all surgeries had been completed successfully. Recurrent vitreous hge. Was developed in patients under renal dialysis with anticoagulant and therapy and un controlling of hypertension and D. M.

### **Intraoperative retinal break**

In our study intraoperative retinal breaks occurred in 18 (20%) cases during removal of epi retinal fibrovascular proliferations.

Our percentage is close to the percentage of intraoperative retinal tears discovered in a series of patients operated by Pendergast, (1998). In his series, intraoperative retinal tears have been encountered in 21% of cases. This is due to the fact that the retina in diabetics is ischemic, moreover the vitreoretinal relationship in patients with diabetic retinopathy is abnormal thus overly aggressive stripping of the posterior cortical vitreous, should be avoided in diabetic patients with an attached hyaloid. Intra operative incomplete removal of proliferative tractinal membrane over main vascular arcades with still detached retina away from the macular area. This complications were recorded in our study in three cases without threatening on V.A., and preserved vision to 6/60 or better.

## Other complications

Other complications related to vitrectomy, as choroidal hemorrhage and endophthalmitis were not detected in the follow up time among the patients of this study.

Cataract extraction (phacoemulsification) with IOL implantation was done during silicone oil removal at least 6 months after surgery.

## Conclusion

90 eyes with PDR invaded central retina and with TRD recovered. Failed anatomical and functional success, secondary to severe diabetic blood insufficiently until ended with fibrosed blood vessels or recurrent fibrovascular tissue proliferation secondary to activation of proliferative cycle, so that the goal of vitreoretinal surgery in central PDR, just prolonged life span of vision long time as possible as in such cases.

## Reference

- Dauglas, M.J., I. U. Scott, Flynn H.W.Jr., 2003. Pars planalensectomy, parsplana vitrectomy and silicone oil tamponad as initial management of cataract and combindtractional/rhegmatogenous retinal detachment involving the macular associated with sever proliferative diabetic retinopathy. *Ophthalmic surgery, laser, imaging : the official journal of the international society for imaging in eye*, 34 (4):270 – 278 .
- Harbour, J.W., W.E. Smiddy and H.W. Flynn and P.E. Rubsamen, 1996. Vitrectomy for diabetic macular edema associated with thickened and taut posterior hyaloid membrane. *Am. J. Ophthalmol*: 121:405-413.
- Ismail-Beigi F., T. Craven, M.A. Banerji, *et al.*, 2010. Accord trial group. Effect of intensive treatment of hyperglycaemia on microvascular outcomes in type 2 diabetes: an analysis of the accord randomised trial. *Lancet*. Aug 7;376(9739):419-30.
- Klein, R., B.E. Klein, S.E. Moss, D.L. DeMets, I. Kaufman and P.S. Voss, 1984. Prevalence of diabetes mellitus in southern Wisconsin. *Am J Epidemiol.*; 119(1):54–61.
- Minami, Y.M., M. Ueki, B. Satoh, T. Ikeda, 2003. Use of perfluorocarbon liquid during vitrectomy for sever proliferative diabetic retinopathy .*Br. J. ophthalmol.* 87:563-566 doi : 10 . 1136 / bjo87.5.563
- Ming, Z. C., Wang Yu., Wang J. Rongetal, 2009. *Journal of otolaryngeal and ophthalmology of Shandong University* vol.23 n 3 pp77-79
- Pastor, J.C., 2011. Vitrectomy for Diabetic Retinopathy .In: Cunha-Vaz J (Ed.), *Diabetic retinopathy* Published by World Scientific Publishing Co. Pte. Ltd. chapter 8; 237-256.
- Pendergast, S.D., 1998. Vitrectomy for diabetic macular edema associated with a taut premacular posterior hyaloid. *Current opinion in Ophthalmology*.9.III: 71-75.
- Pendergast, S.D., T.S. Hassan, G.A. Williams, M.S. Cox, R.R. Margherio, P.J. Ferrone, B.R. Garetson and M.T. Trese, 2000. Vitrectomy for diffuse diabetic macular edema associated with a taut premacular posterior hyaloid. *Am. J. Ophthalmol.* 130: 178- 186.
- Rassam, S.M., V. Patel and E.M. Kohner, 1995. The effect of experimental hypertension on retinal vascular autoregulation in humans: a mechanism for the progression of diabetic retinopathy. *ExpPhysiol*; 80 (1):53–68.
- Smiddy, W.E. and Flynn H.W.jr, (2010). Vitrectomy for diabetic retinopathy. In: Scott IU, Flynn HW Jr, Smiddy WE (Eds.), *Diabetes and Ocular Disease; Past, Present, and Future Therapies*. Published by Oxford University Press .In cooperation with the American Academy of Ophthalmology .207-234.
- Tachi, N. and N. Ogino, 1996. Vitrectomy for diffuse diabetic macular edema in cases of diabetic retinopathy. *Am. J. Ophthalmol.* 122(2): 423- 431.
- Wilkinson-Berka, J.L. and A.G. Miller, 2008. Update on the Treatment of diabetic Retinopathy. *The ScientificWorld Journal.* 8, 98–120
- Wong, T.Y., R. Klein and B.E. Klein, 2010. Epidemiology and Risk Factors of Diabetic Retinopathy. In: Scott IU, Flynn HW Jr, Smiddy WE (Eds.), *Diabetes and Ocular Disease; Past, Present, and*

- Future Therapies. Published by Oxford University Press .In cooperation with the American Academy of Ophthalmology : 71-99.
- Yamamoto, T., N. Akahane and S. Takeuchi, 2001. Vitrectomy for diabetic macular edema: the role of posterior vitreous detachment and epimacular membrane. *Am. J. Ophthalmol.* 132(3):369-377.
- Yang, C.M., 2000. Surgical treatment for sever diabetic macular edema with massive hard exudates. *Retina.* 20(2): 121- 125.